Transrectal Ablation Of Prostate Tissue Using Focused Ultrasound

N.T. Sanghvi[1,2], R.S. Foster[3], R. Bihrle[3], F.J. Fry[1], M. Phillips[1] and C. Hennige[4]
[1]Indianapolis Center For Advanced Research Inc.,
[2]Dept. of Physiology/Biophysics, [3]Dept. of Urology, Indiana University School of Medicine, Indianapolis, IN 46202
[4]Focal Surgery Inc., Milpitas, CA

ABSTRACT

Canine and human prostates were treated with high intensity focused ultrasound (HIFU) using a transrectal probe. Near the beam focus, temperatures were shown to be greater than 60° C, while periprostatic tissue temperatures increased ≤ 3° C; rectal wall temperatures did not rise more than 5° C over the baseline. In 15 patients with benign prostatic hyperplasia (BPH), no major complications resulted from HIFU treatment, and statistically significant improvements in peak and average flow rates were observed at both 90 and 180 days post-treatment.

INTRODUCTION

Noninvasive medical procedures are currently in great demand, both from patients seeking alternatives to surgery, as well as from hospitals attempting to improve cost-effectiveness of treatment (which is highly dependent upon the length of hospitalization and any resultant morbidity or mortality). As well as being the safest imaging modality, ultrasound can also be focused deep within the body to destroy small regions of tissue without causing damage to the intervening layers[1]. If the challenges to endocavity and extracorporeal applications can be met, HIFU may achieve the goal of providing a safe non-invasive outpatient alternative to a variety of surgical procedures.

The design of the system under evaluation (Sonablate™, Focal Surgery Inc., Milpitas, CA) takes advantage of new, highly efficient transducer ceramics and optimized matching layer techniques, such that both ultrasound imaging and HIFU are provided by a single transducer within a transrectal probe. Following extensive research on the ultrasound absorption properties of rectal wall and prostate tissue (and energy level requirements for lesion production), a prototype system was designed to accommodate the necessary safety factors required for transrectal therapy. Subsequently, a formal animal study was conducted, which validated the system's safety for transrectal application of HIFU energy and demonstrated its ability to ablate canine prostatic tissue[2]. Based upon the success of the animal study, a clinical protocol was devised to evaluate the safety and clinical effectiveness in humans.

MATERIALS AND METHODS

The design specifications of the Sonablate system have been previously

1051-0117/93/0000-1207 $4.00 © 1993 IEEE

presented[3]. Briefly, a 4 MHz, curved rectangular transducer (30 mm x 22 mm) housed in an intracavity transrectal probe is used for both imaging and ablation. The transducer is made from a modified Lead Titanate ceramic (Etalon, Lizton, IN); the entire crystal surface is excited with high voltage RF during HIFU application, and the central 12 mm diameter scribed segment is used for imaging. A volume lesion is created in the prostate by mechanically steering the transducer in axial and transverse planes via a computer-controlled interface. A water-filled sheath provides coupling with the rectum and allows adjustments to be made for control of the focal depth. The system was configured to generate a focal site intensity (I_{spta}) of 1680 Watts/cm^2 during a treatment cycle of 16 seconds (4 seconds on, 12 seconds off).

Thermometry was performed during animal studies using flexible wire, T-type bead thermocouples (typically 50 μm, noninsulated) to collect data from the rectal wall and inside the prostate. Thermocouple placement was carried out under real-time ultrasound guidance (Hitachi EUB 410, 5 MHz transrectal linear and phased array system). Data was sampled every 0.5 second and digitized by a sixteen channel LT-100A device (Labthermics Technologies, Champaign, IL) and stored in a PC for later analysis. For rectal wall measurements, the thermocouple was placed between the sheath and the rectum and held in place by a silk thread supported by the sheath. The probe was generously covered with coupling gel and gently placed inside the animal. The therapy zone was carefully selected to coincide with placement of the thermocouple. In one animal, an attempt was made to measure the temperature rise at the therapy focus. For this experiment, the bare thermocouple was threaded thorough an 18 gauge needle, which was inserted into the prostate and positioned under ultrasound guidance. The needle was carefully extracted, leaving the thermocouple in the focal zone.

Additionally, fifteen BPH patients were treated with HIFU between September 11 and November 16, 1992 at the Indiana University Medical Center[4]. As required by the U.S. Food and Drug Administration, periprostatic temperature measurements were obtained on the first ten patients using methods similar to those followed during canine studies, except for the type and location of thermocouples. In humans, three 21 gauge, 13 cm long stainless steel thermocouple needles (Physitemp Instruments, Clifton, NJ) were placed via the perineum to assure that any temperature elevations outside of the prostate would not be sufficient to cause unintentional trauma. Stainless steel sheaths were chosen to provide mechanical strength, sterility, and to minimize interaction with the ultrasonic beam. Each needle held three electrically-isolated 0.15 mm T-type thermocouples spaced at 1.5 cm intervals.

Figure 1 schematically depicts needle placement during the human trials, and Figures 2a and 2b show the increased echogenicity that aided localization of the needles in the transverse and axial scans, respectively. Other tests performed pre- and post-operatively included transrectal ultrasound imaging of the prostate

uroflowmetry, and patient completion of the American Urological Association (AUA) symptom score questionnaire. In some patients, transrectal MRI imaging was also performed, in order to identify tissue changes resulting from the ablative process.

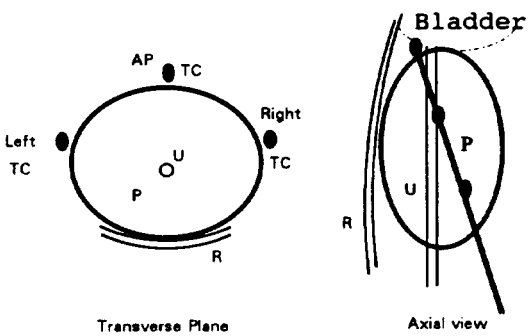

R = Rectum, P = Prostate, U = Urethra
TC = Themocouple

Figure 1. Thermocouple placements in patients.

RESULTS

Temperature levels in the canine prostate in the proximity of the focal zone reached 64°C. This was computed by back extrapolating the temperature decay curve in Figure 3. However, it is possible that the tissue temperature could have been underestimated if the thermocouple had not been located precisely in the focal plane. All rectal wall temperature increases recorded during these experiments remained below 5° C.

Analysis of the thermometry data from all patients demonstrated that no sustained periprostatic temperature rise exceeding 3° C occurred during a standard course of therapy. In one patient with a prostate less than 25 mm in A-P dimension, a transient rise of 17° C was recorded

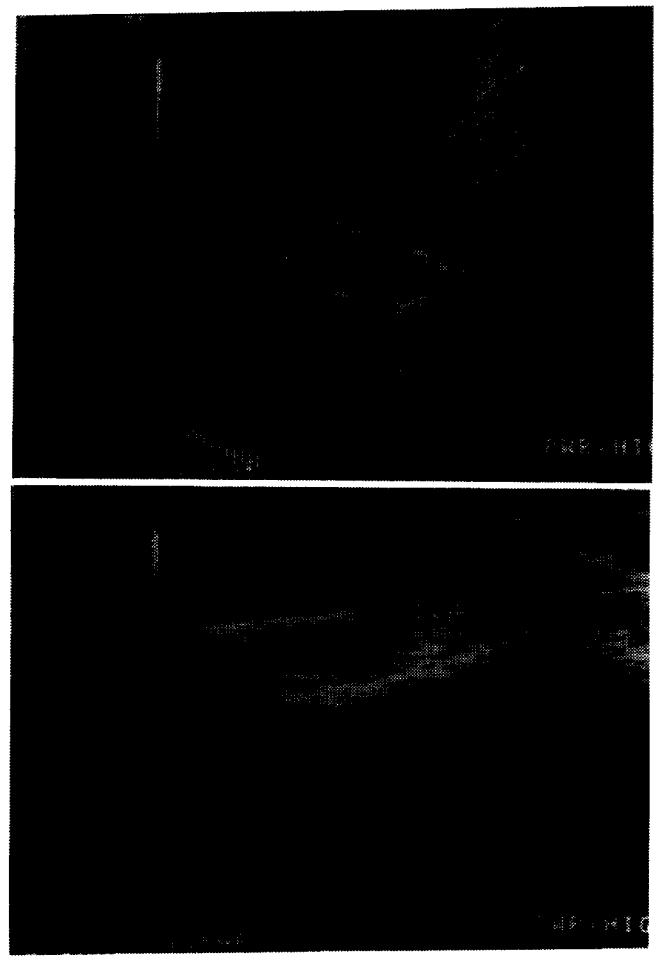

Figure 2a (Upper panel) and 2b (Lower panel) Transverse and Axial ultrasound scans of prostate. Needls are identified by brighter echoes in the periprostatic tissue.

(Figure 4). This rise in temperature lasted less than 4 seconds, indicating that its cause was due to ultrasound/heat conduction by the metallic needle.

As a group, the patients showed a statistically significant improvement in urinary flow rate and symptom scores. The average and peak flow rates increased from 4.24 ($\sigma = 1.64$) to 7.21 ($\sigma = 3.17$, $P < 0.005$) ml/sec and from 9.25 ($\sigma = 3.62$) to 13.95 ($\sigma = 5.34$, $P < 0.005$) ml/sec, respectively, 90 days post-treatment. These improvements remained

relatively stable at the 180 day examinations. No significant complications were observed in this group of patients. It should be noted that although improvements were observed in the majority of patients, the benefit was not universal. A randomized multi-center clinical trial is currently underway to determine the factors which may be most predictive of clinical success.

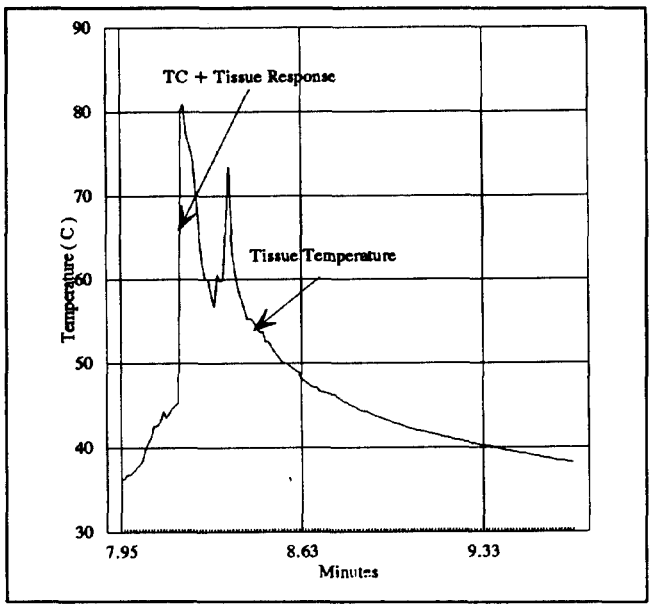

Figure 3. Temperature data inside canine Prostate during HIFU treatment.

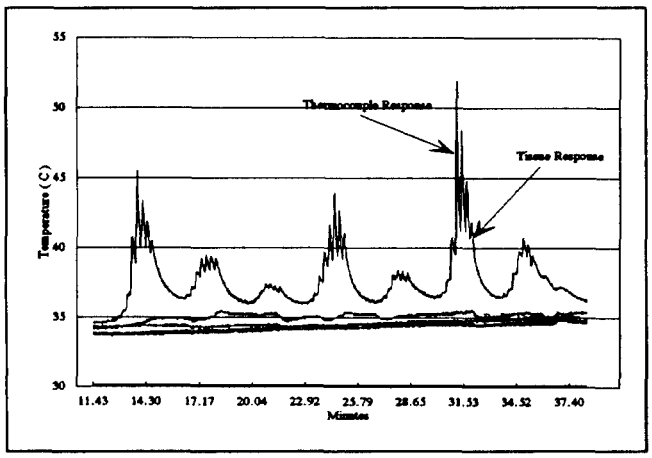

Figure 4. Transient temperature rise in a patient with prostate A-P dimension < 25 mm.

CONCLUSION

This study demonstrates that discrete prostatic lesions can be produced using HIFU without significantly raising the temperature of surrounding tissue. In humans, this has resulted in clinical relief from the symptoms of BPH for a majority of the fifteen patients treated to date. This study is encouraging as it shows progress toward integrating ultrasound imaging with HIFU for a unique noninvasive approach to treatment of neoplastic disease. Further research into the interactions of ultrasound with various tissues are likely to increase the accuracy and reliability of this technique for wide range of applications.

ACKNOWLEDGMENT

The authors wish to thank Dr. K. Kopecky, P. Futch, P. Hood and staff of the indiana University School of Medicine Dept. of Urology for their technical help during these studies.

REFERENCES

[1] W.J. Fry, W.H. Mosberg, J. W. Bernard and F.J. Fry: Production of focal destructive lesions in the central nervous system with ultrasound. J. Neurosurg. Vol 11, pp. 471-478, 1954.

[2] R. S. Foster, R. Bihrle, N. T. Sanghvi, et al.: Production of prostatic lesions in canine using transrectally administered high intensity focused ultrasound. European Urology 1993; 23: pp. 330-336.

[3] N. T. Sanghvi, R. S. Foster, F. J. Fry, R. Bihrle, C. Hennige and L. V. Hennige: Ultrasound Intracavity System for Imaging, Therapy Planning and Treatment Of Focal Disease, IEEE 1992 Ultrasonics symposium Proceedings, Vol. 2: pp. 1249-1253 ISSN1051-0117

[4] R. Bihrle, R. S. Foster, N.T. Sanghvi, et al: High intensity focused ultrasound for the treatment of BPH: Early U.S. clinical experience. J. of Urology (In press)