FREQUENCY DOMAIN TECHNIQUES FOR ULTRASOUND BREAST IMAGING

Elizabeth Kelly-Fry, Sc.M., Ed.D.,[+*] Valerie P. Jackson, M.D.[+] and Narendra T. Sanghvi, M.S.[*]

Indiana University School of Medicine[+] and Indianapolis Center for Advanced Research[*]

The primary purpose of this study is to determine whether certain ultrasound frequency ranges and frequency bands will yield distinct differences in ultrasound pulse-echo image characteristics of benign and malignant breast masses as a result of back scattering changes. It is well established that the ultrasound back scattering strength is dependant on the backscattering particle size, particle distribution and structure and is a function of interrogating frequency of the beam.

The experimental approach is to incorporate a tunable receiver (designed to control center frequency and bandwidth)* into a standard dedicated ultrasound mammography system and to apply this system to examine the breasts of patients known to contain a solid mass. This receiver system was incorporated into a Labsonics, Inc. automated breast scanner in a manner which allowed either the standard, wide band-pass receiver or the tunable receiver to be used. Mammograms were obtained using dedicated low-dose screen-film units. Patients were chosen on the bases of prior knowledge, by x-ray or ultrasound mammography, of the presence of a solid mass within the breast.

Preliminary patient data indicates that this tunable receiver system may allow more precise differentiations between images of fibroadenomas and images of malignant masses than is currently provided by standard breast imaging systems. This conclusion is based on the comparison of breast images of the same patient obtained with a standard wide bandwidth receiver system and those obtained with the tunable receiver system and the confirmed pathology diagnosis. It has also been found that when a high frequency transducer is applied (10 MHz or above) in conjunction with a tunable receiver, set to provide appropriate bandwidth filtering, that the images exhibit high contrast between a breast mass and surrounding tissue.

Since the application of a high frequency examining ultrasound beam, in conjunction with a tunable receiver, allows increased contrast between an overt mass and surrounding normal tissue, this technique should allow improved detection of small breast masses. Further, such selective frequency systems may improve differentiation between fibroadenomas and malignant masses due to differences in the amount of scattering by the internal components of the tumors. Continued improvement of instrumentation which combines the application of high frequencies and a tunable receiver may eventually allow diagnostically precise image characterization of benign and malignant masses.

*Receiver system designed by S. T. Morris of Labsonics, Inc., Mooresville, In.

Published
Amer. Col. of Radiol. 24 Natl. Conference on Breast Cancer, New Orleans, La. March 1990

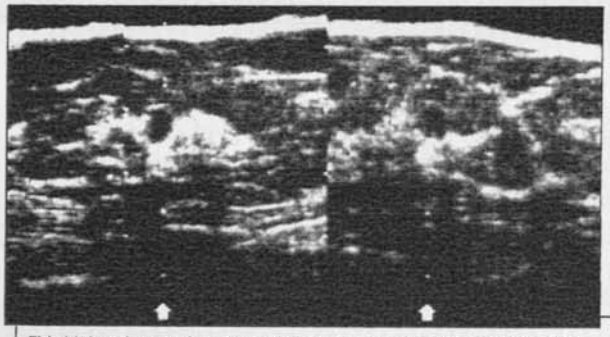

This biplane image of a breast with a small cyst point was obtained with a standard wide-band width scanner and 7.5 MHz transducer.

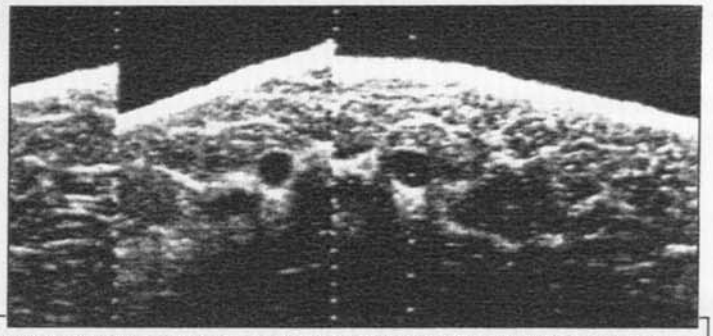

This image was also obtained at 7.5 MHz, but using the tunable receiver system. The improved resolution is the result of bias toward the high frequencies.

Tunable receiver distinguishes fibroadenoma, malignancy

NEW ORLEANS—With a tunable receiver, sonographers may detect small breast masses, as well as differentiate between normal breast tissue and lesions, and between fibroadenomas and malignancies.

"Advantages of the tunable receiver are increased resolution, controlled contrast, and possibly tissue characterization," explained **Elizabeth Kelly-Fry,** a physicist at the Indiana University School of Medicine and the Indianapolis Center for Advanced Research (ICFAR).

FIBROADENOMA PATTERN

Preliminary indications are that the US scanner can be tuned so that fibroadenomas exhibit a distinctive pattern. "We are particularly enthusiastic about its possibilities in terms of fibroadenoma masses," she said.

However, "at this time, we do not claim that all fibroadenoma masses will have this type of pattern; we need to do a great deal more investigation," she added.

Coauthors of this paper, presented at the 24th National Conference on Breast Cancer, sponsored by the American College of Radiology, are **Valerie P. Jackson, MD,** of IUSM, and **Narendra T. Sanghvi, MS,** of ICFAR.

The basic unit used in this study was a Labsonics automated scanner, which normally uses a frequency of 7.5 MHz, and which can scan a mass in both the longitudinal and transverse planes, presenting the acquired data in a single image, so-called biplane scanning. This unit also has the unique ability of pulsing an 11 MHz transducer in a manner which allows center frequency outputs of either 11.0, 6.5, 4.5 or 3.5 MHz.

MORE RESOLUTION

Into this automated scanner, the researchers plugged a tunable receiver to control both the center frequency of the receiver (3.5-15 MHz) and the fractional bandwidth (35-100%).

"We want to increase resolution, which we hope to do by biasing the receiver system for very high frequencies, and by decreasing the bandwidth," Dr. Kelly-Fry explained.

We would like to concentrate our efforts on using this system to influence backscattering

Goals of this research were to improve detection of small breast masses by increasing resolution, and to provide increased diagnostic information, especially in terms of tissue characterization, by biasing toward high frequencies.

In her presentation at the NCBC, Dr. Kelly-Fry offered several sets of images comparing standard scans with tuned scans. In each case, either resolution was increased or masses were more definitely imaged.

IDENTIFYING THE MASS

This study only included women whose x-ray or standard US mammograms showed a solid mass within the breast. These researchers did not simply set the tuner at the high-frequency end, but often compared tuned images to form a diagnosis.

However, in several cases, the high-frequency signal gave the scanner enough contrast resolution to differentiate, for example, a mass from a shadow adjacent to it.

Although using this system to detect small masses is definitely in the works for this team, "at the moment, we would like to concentrate our efforts on using this system to influence backscattering," Dr. Kelly-Fry said.

Backscattering refers to the ultrasound energy "scattered back to the ultrasound probe; the degree of backscattering is related to the frequency," she said.

FUNDAMENTAL DIFFERENCES

"Since the extent of the frequency dependence of backscattering varies according to the basic structure of the tissue, we hope we can get tissue characterization based on frequency dependence," she added.

She offered the case of a woman with a very fatty breast, which had a mass that defied definition on mammography or standard US imaging. "We could not see the internal structure, so we simply narrowed the bandwidth, to a small degree. In other words, we didn't use the highest frequencies, and we could see immediately that this mass was solid," Dr. Kelly-Fry said.

She also offered images of a mass that proved, on biopsy, to be a fibroadenoma. "There is considerable backscattering from all regions of the breast, but there also is a characteristic pattern in the internal structure of the fibroadenoma," she pointed out.

This pattern was highlighted by using the tunable receiver to attain a very narrow bandwidth, biased toward a higher frequency. The phenomenon was reproducible.

Applying the same parameters to a medullary carcinoma yielded different results. "We certainly saw the jagged wall; it was not completely attenuating," she noted. "With the medullary carcinoma, we do not get this intensive backscattering" that the fibroadenoma produced.

Applying the system to a ductal carcinoma offered similar results. "In this case, we only slightly narrowed the bandwidth; we did not try for the highest frequencies for this image," Dr. Kelly-Fry said.

The image showed "the rather [illegible] interior wall characteristic of some malignant masses [illegible] failed to attenuate completely and did not produce intensive backscattering, which was reminiscent of the medullary carcinoma.

"When we narrowed the bandwidth even further, there was no backscattering from the malignant masses. So, clearly this is a very distinctive difference between the backscattering characteristics of the malignant masses and the fibroadenomas," Dr. Kelly-Fry concluded. ■

reported by Bill Edelman, RT staff writer

for more information, please write:
Dr. Elizabeth Kelly-Fry
Wishard Memorial Hospital
Department of Radiology
1001 W. 10th St.
Indianapolis, IN 46202

An image obtained with a standard scanner well demonstrates a fibroadenoma in the breast of a 45-year-old woman.

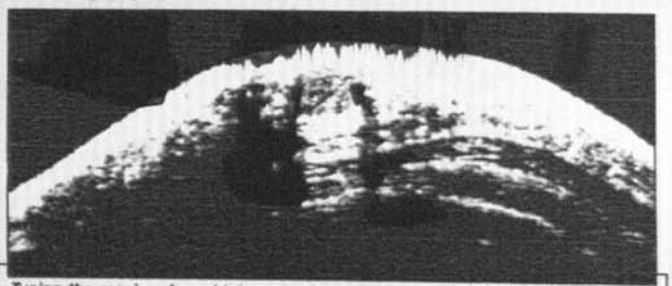

Tuning the receiver for a high center frequency and very narrow bandwidth better defines the internal structure of the mass (note the cyst).