55

Determination of topologic human brain representations and modifications of signs and symptoms of some neurologic disorders by the use of high level ultrasound

Russell Meyers, Frank J. Fry, William J. Fry, Reginald C. Eggleton, and Donald F. Schultz

THOSE ASPECTS of high intensity, focused ultrasound which make it especially useful for elucidating and inducing changes in brain mechanisms subtending certain neurologic disorders and thus for modifying their clinical manifestations have resulted from extensive experimental animal studies carried out during the past decade by several of us (Messrs. Fry and associates). These studies, making use of precisely controlled dosages of ultrasound, have led to several initial discoveries and published reports that may be synopsized as follows:

1] Permanent lesions of arbitrarily predetermined size, shape, and orientation can be produced at any site(s) in the brain. No disruption of intervening tissue is thereby entailed.[1–5]

2] Changes in function of the tissues can be achieved by suitable modification of the parameters of irradiation. Such changes can be both short-lived ("reversible") and enduring ("irreversible").[6] The reversible changes need not be attended by histologically identifiable lesions.[7–10] Here again, intervening tissues regularly escape demonstrable disruption.

3] The vascular system can be left anatomically intact and functioning in cerebral regions in which all neuronal elements (neurocytes and/or their fiber processes) are destroyed.[1–5,11]

4] Fiber tracts of white matter can be interrupted without damage to neighboring or surrounding gray matter that receives an equal dose of ultrasound.[1,3,5,11,12]

5] Mortality and morbidity are extremely small if brain structures not directly involved in mediating vital functions and the responsive state ("consciousness") are not irradiated to produce enduring changes.

6] Evidence thus far obtained indicates that cumulative effects (comparable, for example, to those induced by x-rays and high energy particle radiation) are not produced.

7] Strong presumptive histologic evidence is at hand to indicate that differential susceptibilities to ultrasound exist, in addition to those cited in items 3 and 4. With appropriate choice of the parameters of irradiation, myelin sheaths appear more vulnerable than axis cylinders.

In consequence of these disclosures, it appeared feasible to employ ultrasonic procedures for investigating and modifying the mechanisms underlying certain neurologic disorders in man. Accordingly, we performed during the past one and one-half years 46 ultrasonic irradiation procedures on 41 patients. The disorders to which our attention has been directed are:

Hyperkinesia, the patterned tremors in park-

From the Division of Neurosurgery, State University of Iowa, Iowa City, and the Biophysical Research Laboratory, University of Illinois, Urbana.

Paper presented with motion picture illustration at the eleventh annual meeting of the American Academy of Neurology, Los Angeles, April 18, 1959.

Partially supported by grants from the Parkinsons Disease Foundation, the Easter Seal Research Foundation, and by Grant B1955 with the Institute of Neurological Diseases and Blindness, National Insttutes of Health, U. S. Public Health Service.

Reprinted from NEUROLOGY, Minneapolis, March 1960, Vol. 10, No. 3

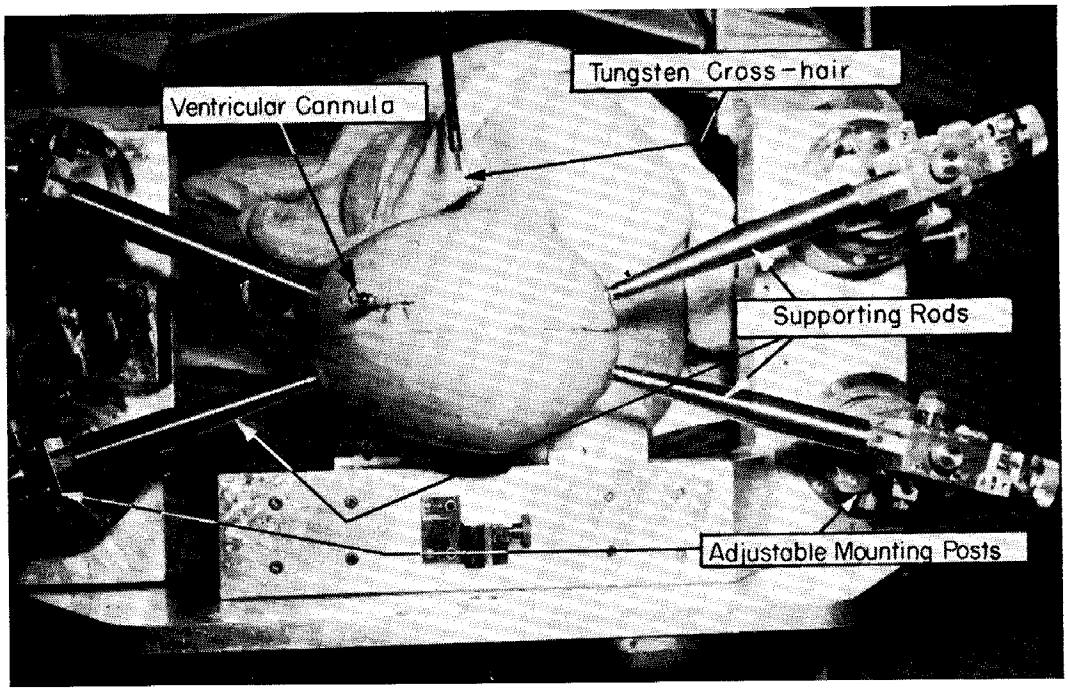

Fig. 1. Close-up of patient mounted in the head holder. The 4 supporting rods (by which the cranium is held rigidly in position) and their corresponding adjustable mounting holders or posts are also illustrated. See the text description of Figure 2 for information on the tungsten crosshair.

insonian patients and the nonpatterned, abnormal movements in cerebral palsied and dystonic patients

Hypertonus, the sustained, usually progressive rigidity in parkinsonian patients and the fluctuating, relatively nonprogressive rigidity ("tension") in athetotic and dystonic patients

Bradykinesia, micrographia, and deficient automatic associated movements in parkinsonism and certain other disorders

Intractable pain—phantom limb and stump pains in amputees, thalamic pain (Déjèrine's syndrome), and the pain of postherpes zoster

Hyperalgesia, hyperesthesia, paresthesias, and dysesthesias in or neighboring upon regions afflicted by amputation stump, thalamic, and postherpetic pains

Phantom limb image in amputees

TECHNIC

Geometric distributions of various brain structures (or parts thereof), the disruption of which modifies the signs and symptoms of the disorders listed above, are determined by placing a number of selective ultrasonic lesions in each patient's brain. The conscious patient cooperates for "objective" neurologic examinations and verbal interviews during and after the production of a lesion at each position.

The technic employed in our first 40 human cases has been described in previous publications.[10,13,14] Experience with these early cases suggested certain advantages that might be gained by revising our original modus operandi. Such revisions have recently been implemented. The technic currently in use and the reasons that prompted adoption of departures from the original may be briefly summarized as follows:

As previously, the reclining position is used to expose the lateral aspect of the patient's head. The cranium is held rigidly by 4 stainless steel rods, the rounded tips of which engage superficial "dimples" (hemispheric tipped indentations 0.5 mm. in diameter and 2.5 to 3 mm. in depth) drilled in the outer table and diploe via short incisions in the scalp (Fig. 1). Each rod is clamped in an adjustable holder by

a device that permits micrometric determination and, later, reduplication of its position in space.

After the patient's head is firmly secured by the rods, lateral and longitudinal (A-P or P-A) cranial roentgenograms are made with radiopaque material (colloidal thorium dioxide 25%, 3 cc.) mixed with the cerebrospinal fluid in the ventricles. The brain coordinate landmarks provided by the lateral ventriculogram are the ventricular boundaries of the anterior and posterior commissures. The landmark provided by the longitudinal ventriculogram is the midline of the third ventricle. The x-ray tubes for obtaining the lateral and longitudinal ventriculograms and their corresponding cassettes are mounted in reproducible positions on the head holder (Fig. 2).

The positioning system seen in the central part of Figure 2 supports and moves a tungsten cross hair (embedded in a plastic rod). The images of this cross hair appear on the ventriculograms and are used in the determination of the coordinates of the brain site(s) to be irradiated. Coordinate lines are drawn on the films, and measurements of the projected images of the commissural landmarks, midline of the third ventricle, and tungsten cross hair are made. The tungsten cross hair referred to replaces the tapered metal rod pointer used in the earlier technic, upon which we have reported.[10,13]

In the original technic, the patient was removed from the head holder after the ventriculograms were made. He was then brought back at a later time (but not sooner than four or five days) and repositioned in the head holder for reflection of a lateral scalp flap, craniectomy, and ultrasonic irradiation. Immediately after irradiation (unilaterally or bilaterally, as desired), the bone flap was replaced and scalp closure effected.

In this method, 3 serious disadvantages inhere. First, if any repetition and/or extension of irradiation should subsequently be indicated, reelevation of scalp and bone flaps would be required. Second, the patient about to undergo a period of ultrasonic irradiation (for which his sustained cooperation is a necessary precondition) is required to endure the physiologic and psychologic stresses related to reflection of scalp and bone flaps. Third, while many clinical changes manifest themselves either immediately or within a period of minutes to an hour or two following exposure at an array of positions, other changes require several days or even months for their evolution. For example, in some parkinsonian patients tremor and/or rigidity may be completely abolished on the operating table only to return to some degree within a few days, weeks, or months after irradiation. A similar circumstance may occur in patients subjected to operation for relief of intractable pain.

For all these reasons, it appeared desirable to devise a procedure to eliminate the disadvantages mentioned. Such has been accomplished by irradiating through the intact skin in patients from whom an appropriate bone flap has been removed at some convenient time prior to implementing ultrasonic irradiation.[15] At the time of removal of the bone flap, ventriculography is performed during general anesthesia. The patient's head is secured, as previously described, in the head holder. Immediately following ventriculography, the scalp flap is elevated and the bone flap removed and stored for later replacement. A thin sheet of polyethylene may be inserted to prevent the formation of adhesions between scalp and dura. The scalp is then sutured and a plaster dressing applied. Where desirable, a light,



Fig. 2. The patient mounted in the head holder. The x-ray tubes and film cassettes, the positioning system which supports and moves the tungsten crosshair, and the crosshair are illustrated.



Fig. 3. Arrangement of patient, head holder, hopper, ultrasonic irradiator (shown partially immersed in degassed saline within hopper), and irradiator coordinate positioning system for implementing high level focused ultrasonic irradiation of an array of sites in the brain. Irradiation through the *intact* skin is being carried out. (The coupling transformer, mounted on the irradiator positioning system, permits electrical matching of the irradiator load to the electronic driver.)

fiberglass helmet can be furnished to provide protection.

At some convenient time after scalp healing has taken place, the patient, now in a fresh state, is repositioned in the head holder. To this end, the short, healed scalp incisions in the forehead and occipitoparietal regions are reopened during local anesthesia for admission of the supporting rods. Ultrasonic irradiation can now be effected through the intact scalp. *This procedure can be repeated* with a minimum of inconvenience *as often thereafter as is desired.*

The procedure originally described—that of employing a bottomless "pan" or hopper for supporting the degassed saline through which the ultrasonic beams are transmitted from source to tissue—has been retained in principle with the following important technical modification. A water-tight seal between hopper and skin surface is accomplished by means of a pneumatic gasket that avoids suturing of the scalp to pan. If the skin incisions permitting access of the supporting rod tips to the 4 cranial "dimples" are suitably protected, the procedure described can be conveniently accomplished without the necessity of resorting to aseptic-sterile technics (Fig. 3).

Ultrasonic irradiation is now accomplished at a suitable array of sites within or on the boundaries of one or several brain structures determined by [1] subjective and objective changes arising during the irradiation sequence on the patient and [2] experiences accumulated from previous procedures on other patients. Following each individual "exposure," subjective and objective neurologic and psychologic tests are carried out. The patient's performances are recorded and, in appropriate instances, are documented in the form of motion picture and sound tape recordings. In such circumstances, the patient remains in good condition—alert, clear, cooperative, and able to help himself from the operating table at the termination of the procedure.

A period of postoperative observation follows each irradiation procedure. Long-term changes are evaluated with a view to deciding whether additional irradiation is indicated. After the patient has been followed clinically for a sufficient period of time to indicate that such favorable changes as have been brought about are relatively sustained, the patient's bone flap can be replaced as a free graft or, if preferred, an acrylic plate may be substituted for it.

CEREBRAL STRUCTURES CURRENTLY UNDER INVESTIGATION

The clinical results obtained in the first 12 cases have been reported upon in detail[13] and will not be reiterated here. It is not within the scope of the present paper to synopsize the results obtained in 30 subsequent cases subjected to ultrasonic irradiation. Such will be made the basis of a separate report. Our intention here is, rather, to cite those cerebral structures, certain parts and/or boundaries of which have been made ultrasonic target regions, and to describe certain of the physiologic and psychologic effects arising from their irradiation.

In the first patients manifesting the tremor and rigidity of Parkinson's disease, the arrays of sites at which the common focus of the

ultrasonic beams was directed corresponded to the region of the ansa lenticularis medial and ventral to the medial segment of the globus pallidus. This procedure proved in some patients insufficient to relieve all tremor and rigidity of the contralateral limb(s). Moreover, the proximity of certain nuclei of the hypothalamus, optic tract, and genu of the internal capsule to the pallidofugal complex invited untoward complications.[13] A search was therefore instituted for other structures in which an array of ultrasonic lesions might prove effective for favorably modifying tremors and rigidity, economical in respect of the volume of tissue required to be irradiated, and "safe" as regards the advent of unintended neurologic deficits. Portions of the following structures were selected for irradiation because they are known anatomically to be related to the pallidofugal complex: the posterior part of the substantia nigra and/or its superior medial border; the base of the ventrolateral nucleus of the thalamus; the tegmental field of Forel; the zona incerta; and the fiber tract regions, H_1 and H_2.

In these structures, it has been possible to exhibit spatial distributions of neural components, irradiation of which results in the modification of tremor and/or rigidity in various muscle groups of the body. Of course, much further work is required to establish the details of these distributions. However, from the data now at hand, it is apparent that tremor and rigidity are not necessarily simultaneously modified, although in some cases they have proved to be so.

Our data indicate that an anterior-posterior topologic distribution of neural elements, corresponding to groups of muscles of the head, neck, upper limbs, trunk, and lower limbs, respectively, primarily involved in the mechanism of rigidity but also entering into the mechanism of tremor is present in the basal part of the ventrolateral nucleus of the thalamus and that a similar distribution, involved primarily in the mechanism of tremor, is present along the border of the posterior part of the substantia nigra.

In addition to irradiating the above-named structures in cases of parkinsonism, we have irradiated them in cases of athetotic cerebral palsy, dystonia musculorum deformans, and other variants of nonpatterned hyperkinesia which, up to the present, have not been given a formal clinical designation.

Patients manifesting various types of chronic intractable pain have also been subjected to ultrasonic radiation directed at sites within and/or on the boundaries of various structures of the dorsal thalamus, namely, the ventroposterolateral, ventroposteromedial, central median, dorsomedial, and lateral posterior nuclei. The types of cases studied in this way have included amputation stump, phantom, thalamic (Déjèrine's), and postherpetic pains.

The first patient presented amputation stump and phantom pain as well as a phantom image of the right upper limb. Unilateral irradiation directed at sites in the ventroposterolateral nucleus of the thalamus was employed. During operation, the stump and phantom pains were eliminated and remained in abeyance for approximately three months. Similarly, the phantom image and dysesthesias in the stump were eliminated at the time of irradiation, only to recur with the return of the pain in the stump.

In this patient, some neurologic deficits in the lower limb and trunk ipsilateral to the amputation stump were produced (hypalgesia, hypesthesia, pallhypesthesia, and partial acragnosis). During the fifth postoperative week, the patient noted the development of a "sunburn-like" discomfort of the right cheek. This rapidly spread to involve the remainder of the right side of the body. The "sunburning" subsequently assumed the character of a typical thalamic (Déjèrine's) syndrome.

Because of the recurrence of the original symptoms and the development of thalamic pain in this patient, a more medial irradiation was carried out on a second case of amputation stump and phantom pain with phantom image of the left upper limb. The patient was completely relieved of pain in the stump and phantom, of tenderness and dysesthesias in the stump, and of the phantom image. He exhibited no postoperative sensory, motor, coordinative, or psychologic deficit. The original symptoms began to recur in about eight weeks and became troublesome during the fourth postoperative month. Up to the present time, no symptoms suggestive of thalamic pain have been described by this patient.

In the first case of Déjèrine's syndrome sub-

jected to ultrasonic irradiation directed at sites in the medial part of the ventroposterolateral and ventroposteromedial nuclei, no favorable or unfavorable modification of the thalamic pains and dysesthesias ensued. However, when, in a second patient suffering from thalamic pain, the common focus of the ultrasonic beams was directed at the basal-lateral part of the border region of the centromedian nucleus, the pains and dysesthesias were completely eliminated during and after operation for several weeks. No neurologic deficit was demonstrable. As in the previously mentioned cases with amputation stump pain and phantom image, this patient reported a partial recurrence of symptoms during the eighth postoperative week. Within another month, they had virtually returned to their preoperative status.

A similar irradiation array to that just described was employed for the relief of severe postherpetic pain, dysesthesias, paresthesias, and tenderness in the distribution of the right ophthalmic division of the trigeminal nerve in a male, aged 70 years. Here again, the discomfort was completely relieved, without imposing further neurologic dysfunction, during the operation. Unfortunately, the patient's symptoms recurred during the sixth postoperative week. The patient reported that only one feature of his preoperative discomfort—a transient sporadic lancinating pain—had not recurred.

A parkinsonian patient died on the fifth postoperative day and another on the seventh. In the first of these, a bilateral pneumonitis and, in the second, complications consequent upon a severely toxic gastroenteritis were revealed at autopsy. In both instances, the patients remained relatively unresponsive during the postoperative period. From the standpoint of achieving a favorable modification of rigidity and tremor, both patients were considered during operation as likely to make appreciable therapeutic gains.

DISCUSSION

The high intensity ultrasonic method of producing selective, arbitrarily shaped arrays of lesions in the nervous system constitutes a more versatile tool than any heretofore employed for studying neural functions and dysfunctions. Looking toward the development of new and/or improved methods for the alleviation of various neurologic and psychologic disorders, it became apparent to us that, in the endeavor to achieve optimal benefit for the greatest number of patients, the use of the ultrasonic tool might be most fruitfully implemented by first employing it to elucidate the pathogenetic mechanisms basic to these disorders. This objective has entailed and continues to entail irradiation of human brain structures, the detailed operations of which are as yet poorly understood. Consequently, the results obtained through the use of ultrasound may be evaluated by considering the extent to which data bearing on the pertinent neural mechanisms have been and are being acquired. In brief, the usefulness of focused ultrasound as a tool in human neurosurgery can be more meaningfully expressed in terms of the rapidity with which it yields information and the extent to which it renders results reproducible than in terms of raw percentages of favorable clinical cases. Indeed, it is at the present time evident that the criterion of "favorable clinical results" cannot provide a useful basis of evaluation, since uncorrelated data resulting from investigations of the functions of a *variety* of cerebral structures cannot be meaningfully grouped together until some unifying schema is evolved. Until the time essential to reaching such a schema has passed, the data resulting from disruption of each specific structure (or of parts and/or combinations thereof) must be considered separately. Obviously, once an irradiation array for obtaining a favorable clinical outcome has been identified and the results obtained by the use of the ultrasonic method have been established as reproducible, any desired number of favorable cases may be produced.

The process of deriving a substantial and predictive unifying schema for any sign (for example, hyperkinesia, akinesia, and hypertonus), symptom (pain, dysesthesias, and paresthesias) or syndrome (parkinsonism, thalamic pain) involves a good deal of systematic spadework at this, our present limited stage of knowledge. The manifest effects of arrays of lesions in target structures, taken singly and in various combinations, must be painstakingly observed, recorded, and later verified. Plan-

ful trial-and-error experimentation and prompt exploitation of newly acquired knowledge, both "positive" and "negative," appear essential to making rapid progress in this area of study.

As mentioned above, the ultrasonic method permits making arrays of lesions so positioned and oriented as to conform to specific neural structures or boundary regions thereof *without* adversely affecting intervening neural tissues. Up to the present, this has not proved possible with any method requiring mechanical penetration of tissues by conventional scalpel, leukotome, electrodes, or cannulas.

It is to be emphasized that the full potential of the ultrasonic method is not realized if the focus of the ultrasonic beam(s) is placed at a single "center" and the ultrasonic dosage parameters alone are employed to control the size of the resulting lesion. The principle just mentioned, that of controlling the size of the lesion from a single "center" by varying the pertinent parameters (for example, time and current in electrocoagulation or quantity of necrotizing agent in chemocoagulation), is of necessity currently employed by methods involving mechanically penetrating instruments.

Finally, in evaluating the ultrasonic method as applied to basic and clinical neurologic problems, one must distinguish on the one hand between *geometric accuracy* of positioning the focus at a site in the space occupied by the brain within the skull and, on the other, *anatomic accuracy* of placement in a specific site in some cerebral structure of interest. The geometric accuracy now realizable appears adequate for any studies we now contemplate. Refraction at the saline-dura interface can result in a 0.5 mm. shift of the focal region lateral to the beam axis if the ultrasound is focused at the greatest depths (10 to 12 cm.) in a human brain and if the angle of incidence is 45°. Smaller angles of incidence result in correspondingly smaller shifts, and, in any case, the irradiator coordinates can be adjusted to correct for the major part of shifts of the focal region resulting from refraction at the saline-dura interface. Anatomic accuracy, on the other hand, is limited by the precision and imprecision of currently available atlases. It may be reasonably anticipated that brain atlases and associated landmarking schemes will continue to be improved, thus enhancing in the foreseeable future the accuracy of human brain stereotaxy.

Since it is now possible to induce reversible changes in neural function(s) by the use of ultrasound, the investigator is fortunately not forced to await the improvement of atlases in order to improve the accuracy of anatomic positioning. In fact, by employing reversible dosages of ultrasound, he stands in a favorable way to contribute basic knowledge in this area. In addition, the construction of a more detailed 3-dimensional model of basic brain functions becomes feasible. Some useful work in this area has already been accomplished.[7–10]

REFERENCES

1. Fry, W. J., Mosberg, W. H., Barnard, J. W., and Fry, F. J.: Production of focal destructive lesions in the central nervous system with ultrasound. J. Neurosurg. 11:471, 1954.
2. Fry, W. J., and Barnard, J. W.: Selective action of ultrasound on nerve tissue. Convention Record, Institute of Radio Engineers, p. 102, 1954.
3. Barnard, J. W., Fry, W. J., Fry, F. J., and Krumins, R. F.: Effects of high intensity ultrasound on the central nervous system of the cat. J. Comp. Neurol. 103:459, 1955.
4. Fry, W. J., Barnard, J. W., Fry, F. J., and Brennan, J. F.: Ultrasonically produced localized selective lesions in the central nervous system. Am. J. Phys. Med. 34:413, 1955.
5. Fry, W. J., Barnard, J. W., Fry, F. J., Krumins, R. F., and Brennan, J. F.: Ultrasonic lesions in the gray and white matter of the mammalian central nervous system. Science 122:517, 1955.
6. Fry, W. J., Wulff, V. J., Tucker, D., and Fry, F. J.: Physical factors involved in ultrasonically induced changes in living systems. I. Identification of non-temperature effects. J. Acous. Soc. Am. 22:867, 1950.
7. Fry, F. J.: Production of reversible changes in the central nervous system by ultrasound. Abstr. Natl. Biophys. Conf., 1957. p. 30
8. Fry, F. J., Ades, H. W., and Fry, W. J.: Production of reversible changes in the central nervous system by ultrasound. Science 127:83, 1958.
9. Fry, W. J.: Unsolved problems in biological and medical acoustics. J. Acous. Soc. Am. 30:387, 1958.
10. Fry, W. J.: Intense ultrasound in investigations of the central nervous system. Advances in Biol. and Med. Phys. ed. J. H. Lawrence and C. A. Tobias, 6:281, Academic Press, New York, 1958.
11. Barnard, J. W., Fry, W. J., Fry, F. J., and Brennan, J. F.: Small localized ultrasonic lesions in the white and gray matter of the cat brain. Arch. Neurol. & Psychiat. 75:15, 1956.
12. Fry, W. J.: Ultrasound in neurology. Neurology 6: 693, 1956.
13. Meyers, R., Fry, W. J., Fry, F. J., Dreyer, L. L., Schultz, D. F., and Noyes, R. F.: Early experiences with ultrasonic irradiation of the pallidofugal and nigral complexes in hyperkinetic and hypertonic disorders. J. Neurosurg. 16:32, 1959.
14. Fry, W. J., Meyers, R., Fry, F. J., Schultz, D. F., Dreyer, L. L., and Noyes, R. F.: Topical differentia of pathogenetic mechanisms underlying parkinsonian tremor and rigidity as indicated by ultrasonic irradiation of the human brain. Tr. Am. Neurol. 16, 1958.
15. Fry, F. J., Fry, W. J., and Meyers, R.: Investigation and modification of the signs and symptoms of neurologic disorders in humans by high level focused ultrasound. Abstr. Biophys. Soc. paper J5, 1959.